

Photorealistic imaging enhances 3D echocardiography in structural interventional cardiology

Dr. Jeffrey S K Chan

Researcher, Prince of Wales Hospital, Hong Kong, China

Professor Alex Lee

Professor of Medicine and Therapeutics, Chinese University of Hong Kong

Director, Echocardiography Laboratory

Prince of Wales Hospital, Hong Kong, China

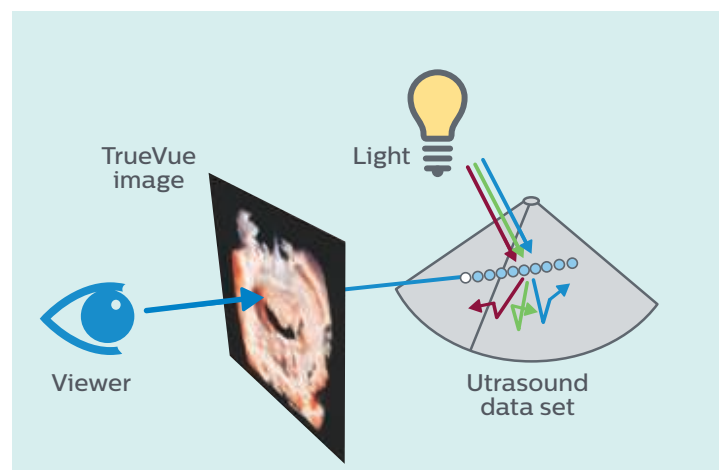
Overview

Three-dimensional (3D) echocardiography has become an essential imaging technique in structural heart disease intervention. Today, the spectrum of diseases that the heart team has to deal with are increasingly complex, as are the available interventional procedures and devices with which to treat heart disease. Optimal methods for displaying 3D images are critical for the perception of depth and to provide a clinically useful understanding of dynamic cardiac anatomy.

TrueVue photorealistic imaging

Conventional 3D rendering uses shading techniques to encode voxels based on their distance, gray-level gradient and texture to generate a 3D display of cardiac structures. Philips TrueVue photorealistic 3D imaging goes beyond this, simulating the interaction of light with tissue, which enables users to illuminate structures within the volume (Figure 1).

Figure 1 TrueVue adds a virtual light source and simulates light-tissue interactions, including absorption, scattering and reflection, resulting in a photorealistic image with shadows that highlight structures and enhance depth perception.



TrueVue provides shadows to facilitate depth perception and motion, improving visualization of the device during an interventional procedure through the use of a virtual light source and a physical model of how light interacts with tissue. With an increase in computing power, the behavior of different wavelengths of light can now be modeled to generate a more realistic image (**Figure 2**).

With TrueVue, the light can be placed anywhere within the volume to illuminate specific structures. This photorealistic imaging enhances the sense of depth and space, producing images that appear more natural and realistic to the human eye, which facilitates the detection of subtle structures and pathologies (**Figure 3**).

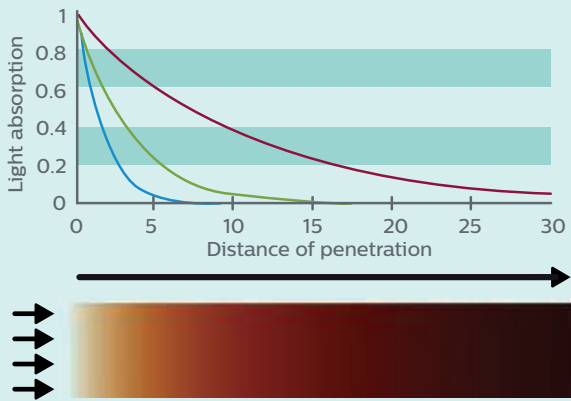


Figure 2 Absorption of light in tissue is wavelength-dependent. TrueVue models this dependency, resulting in darker red hues with increased penetration depth.

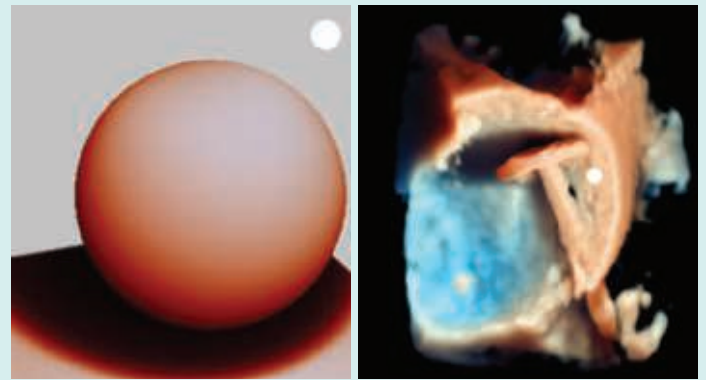


Figure 3 Depiction of TrueVue shadows and scattering demonstrated on a synthetic and a clinical example. The lighting model results in shadowing that transitions smoothly between illuminated and occluded regions.

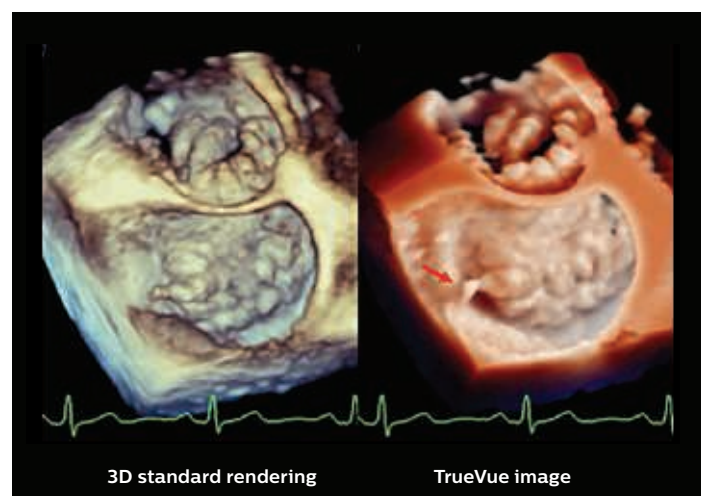
Case studies

Four cases in which photorealistic imaging aided diagnosis for our team.

Case 1

Degenerative mitral regurgitation

3D transesophageal echocardiography (TEE) shows the “surgeon’s perspective” of a case involving diffuse degenerative mitral valve disease. TrueVue photorealistic imaging (right panel) with the light source placed inside the left atrium enhances the virtual shadowing of the prolapsed segments and allows for visualization of a ruptured tendinous cord (arrow) of the A1 segment, as compared to the conventional 3D TEE image (left panel).

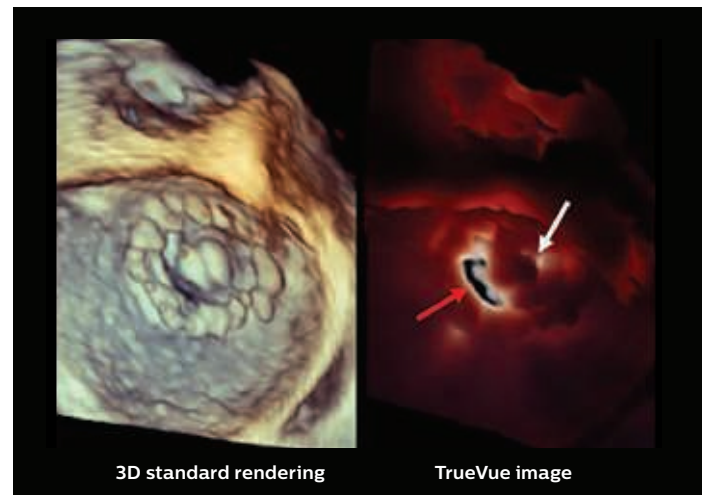


Enhanced visualization in diffuse degenerative mitral valve disease.

Case 2

Obstructive mechanical mitral prosthesis

A patient with a previous mechanical mitral valve replacement underwent 3D TEE for evaluation of the prosthetic valve with abnormal pressure gradient. Upon conventional 3D TEE, it was suspected that the opening of one of the two mechanical leaflets was obstructed (left panel). Photorealistic imaging (right panel) with the TrueVue virtual light source positioned in the left ventricle shows transillumination through the unobstructed orifice (red arrow) with the mobile leaflet, but not through the obstructed orifice with a leaflet stuck in the closed position (white arrow) as a result of pannus overgrowth. Compared to the conventional 3D TEE image, transillumination imaging increases the diagnostic confidence of identifying an obstructive mitral valve prosthesis.

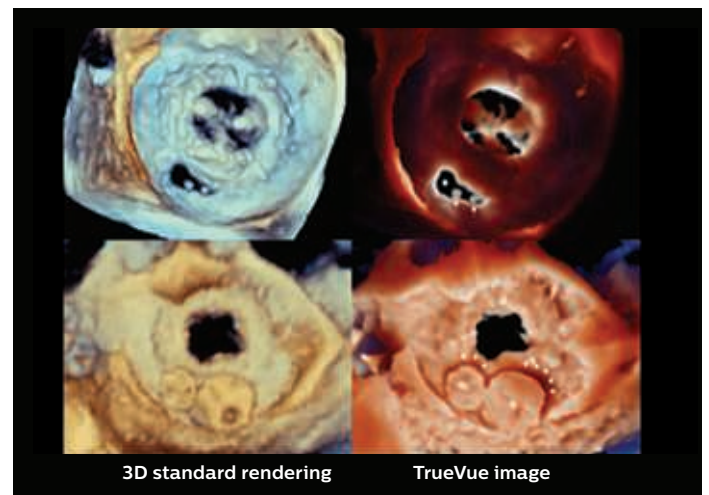


Transillumination aids in identifying an obstructive mitral valve prosthesis.

Case 3

Paravalvular leak of bioprosthetic mitral valve

A patient with a previous mitral bioprosthetic mitral valve replacement underwent TEE for dyspnea on exertion, revealing a paravalvular leak on the posterolateral aspect of the prosthesis. Photorealistic 3D TEE imaging (right upper panel) with virtual light projection from the left ventricle clearly demonstrated the anatomy and location of the paravalvular leak (asterisk in right upper panel), with two loose surgical stitches (arrows in right upper panel), which were presumably the cause of the dehiscence, adjunct to conventional 3D rendering (left upper panel). Transcatheter closure of the paravalvular leak was performed with two vascular plugs. Post-implantation photorealistic 3D TEE with the TrueVue virtual light source placed inside the left atrium confirms sealing of the paravalvular leak.

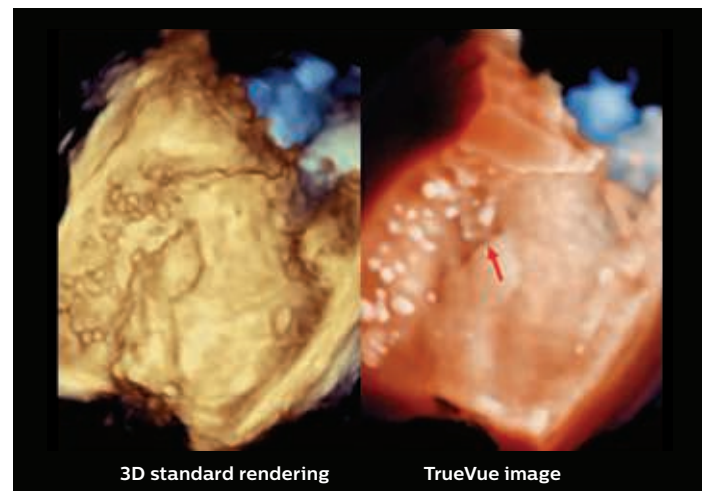


The shadows projected by the vascular plugs on the mitral bioprosthesis (arrows in right lower panel) enhance discernment of the proper alignment between the devices.

Case 4

Cryptogenic stroke

A patient underwent TEE with intravenous agitated saline contrast for evaluation of a suspected patent foramen ovale (PFO) as a cause of cryptogenic stroke. The images show the interatrial septum on 3D TEE from the left atrial perspective. Compared to traditional 3D TEE (left panel), TrueVue photorealistic 3D TEE (right panel) more clearly shows the agitated saline contrast passage through the free edge of a PFO (arrow) on Valsalva release, highlighting the anatomy of PFO flap and the number of bubbles appearing in the left atrium.



Visualization of contrast bubbles and anatomy aids evaluation of the cause of cryptogenic stroke.

Conclusion

TrueVue photorealistic imaging in 3D echocardiography can enhance the interpretation of structural heart disease images and improve communication within the heart team. In many cases this imaging technique can provide crucial clinical information that strengthens understanding of the anatomy and pathology, and alters management for improved patient outcomes.



Dr. Jeffrey S K Chan

Dr. Chan is responsible for the clinical management of general medical diseases, and conducts research in echocardiography, structural cardiac interventions and heart failure as part of Professor Alex Lee's research team at the Prince of Wales Hospital, Hong Kong, China.



Professor Alex Lee

Professor Lee is Professor of Medicine and Therapeutics at the Chinese University of Hong Kong. He is also Director, Echocardiography Laboratory, at the Prince of Wales Hospital, Hong Kong, China, where he performs interventional and peri/intra-operative echocardiography. He focuses on the clinical management of valvular disease, coronary artery disease and heart failure

Results from case studies are not predictive of results in other cases. Results in other cases may vary.

